

***Sarcocystis capracanis* infection in Philippine Domestic Goats (*Capra hircus*): Ultrastructural Studies**

Florencia G. Claveria, Maria Roima San Pedro-Lim,
J. Eric Tan and Mary Jane Flores-Cruz

Biology Department, College of Science
De La Salle University-Manila
Taft Avenue, Manila, Philippines

Tissue samples from the esophageal, neck, diaphragm, and fore-and hind-limb muscles of 11, 3-to-5-yr old domestic goats were infected predominantly with fusiform sarcocysts. Histologic and ultrathin sections had prominent intravascular schizonts in blood vessels and enroute to parasitization of muscle tissue. The sarcocyst wall, 2.3-3.17 μ m thick has palisade-like villar protrusions (VP), 1.1-1.4 μ m apart and contain microfilaments and electron-dense wavy wall. The VP basal proximal segment is broader than the distal portion. The primary cyst wall measured 0.15-0.18 μ m thick and has prominent and evenly distributed unilayered undulations interspersed between the VP. The granular layer 0.66-0.77 μ m thick is continuous with septae enclosing bradyzoites and metrocytes. The ultrastructure of *Sarcocystis capracanis* typifies the Type 14 cyst wall. This documents the first case of *Sarcocystis capracanis* infection in Philippine domestic goats.

Keywords: Sarcocystosis, domestic goats, Philippines

Published reports of *Sarcocystis* species in the goat *Capra hircus* are relatively few (Foreyt 1989; Singh et al. 1990; Saito et al. 1996; Woldemeskel & Gebreab 1996). Three species have been reported in domestic goats worldwide, namely: *Sarcocystis capracanis* Fischer, 1979, *Sarcocystis moulei* Neveu-Lemaire, 1912 (Syn: *Sarcocystis caprafelis* El-Refaii, Abdel-Baki and Sevin, 1980), and *Sarcocystis hircicanis* Heydorn and Unterholzner, 1983 (Dubey 1980; Dubey et al. 1984; Dubey et al. 1989). In the Philippines only the bubaline *Sarcocystis fusiformis* (Railliet, 1897) Bernard and Bauche, 1912 (Tongson & Molina, 1979; Parairo et al. 1988; Claveria & Cruz 1999), the redescribed *Sarcocystis levinei* (Dissanaike and Kan, 1978) Huang, Dubey and Uggla, 1997 (Huang et al. 1997; Claveria & Cruz, 2000), the cattle *Sarcocystis cruzi* (Hasselman,

1926) Wenyon, 1926 (Claveria et al. 2001a) and the swine *Sarcocystis miescheriana* (Kuhn 1865) Labbe, 1899 (syn: *Sarcocystis suicanis* Erber, 1977) (Claveria et al. 2001b) have been identified to date. This paper presents the first documented case of *Sarcocystis capracanis* infection in Philippine domestic goats (*Capra hircus*).

Methods

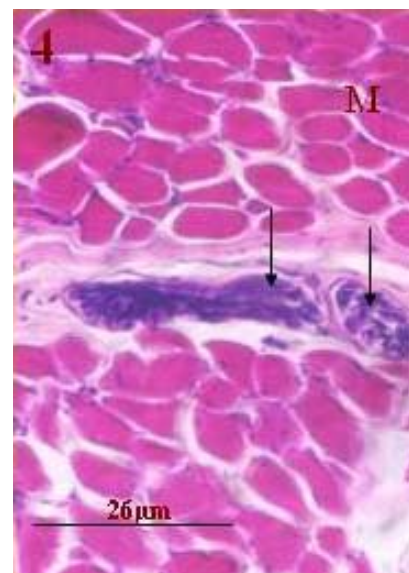
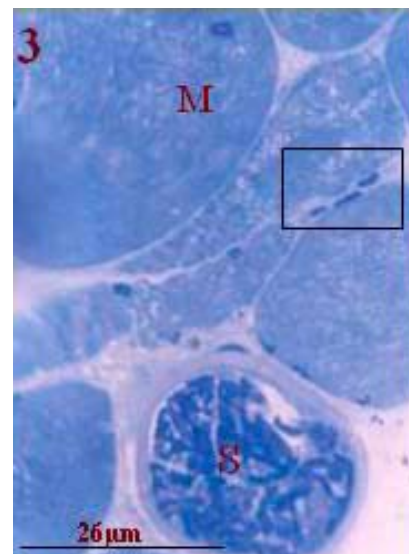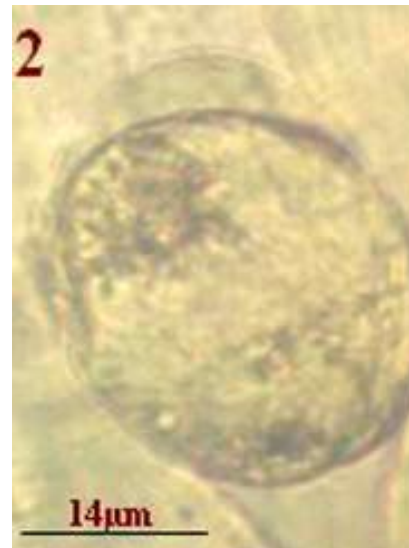Muscle tissue samples were obtained from twenty six 3-to5-yr-old domestic goats grown in the provinces of Batangas, south of Manila and Iloilo, Visayas and slaughtered in Metro Manila. The examination for sarcocysts was limited to muscles of the esophagus, neck, diaphragm and fore- and hind limbs.

*Corresponding author: claveriaf@dlsu.edu.ph

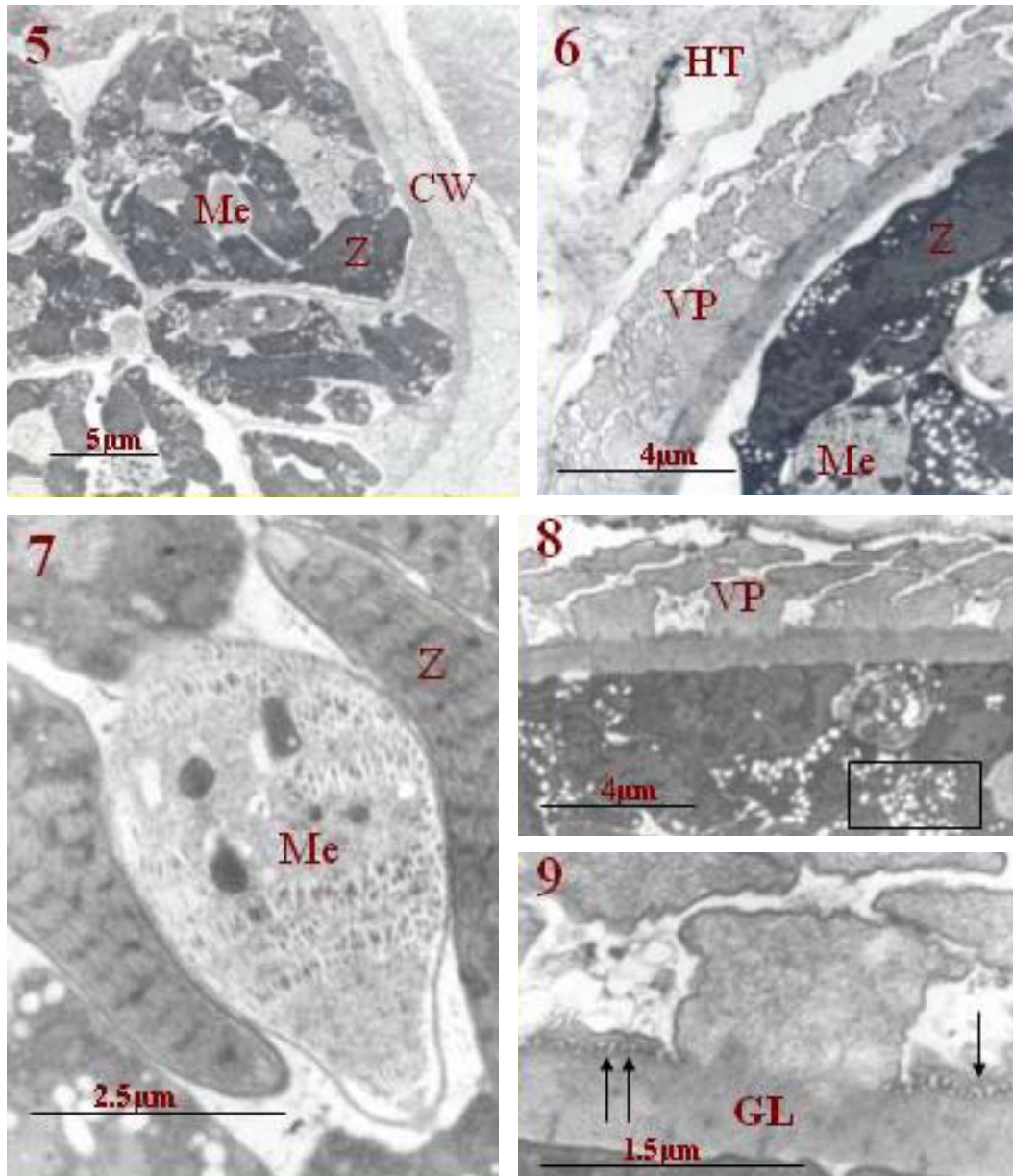
Tissue samples in labeled-plastic bags inside a cooler were brought to the Zoology and Parasitology Research Laboratory at the Science and Technology Research Center, De La Salle University-Manila, and were examined on the day of collection. Tissue samples were initially examined for the presence of macrosarcocysts, and thin muscle slices were then teased lightly and examined for microsarcocysts. Those positive for sarcocysts were fixed in 10% formalin and processed following the standard histologic and H & E staining procedure, and some were fixed in 2.5% cold glutaraldehyde for transmission electron microscopy (TEM). Semithin sections stained with toluidine blue were prepared to aid in the localization of sarcocysts in tissue samples prior to the preparation of ultrathin tissue sections for TEM (Joel-1010, Japan) at the Biomedical Research Center, St. Luke's Medical Center, Quezon City, Manila. The sarcocyst ultrastructure particularly the cyst wall was characterized using the cyst wall sarcocysts types established by Dubey et al. (1989).

Results and Discussion

Eleven goats had microsarcocysts. Muscle tissue samples had few to several fusiform and/or rounded sarcocysts, with the predominance of the fusiform form in the limb muscle. Fusiform sarcocysts measured 100-200 μ m long and 7-31 μ m across, and exhibited compartmentalized zoites (Fig. 1), while rounded



Figures. 1-4. *Sarcocystis capracanis* in limb muscle tissue. 1. Fusiform-shaped sarcocyst showing zoite compartmentalization. 2. Rounded non-septate sarcocyst. 3. Semithin tissue section showing mature sarcocyst (S) and intravascular schizonts (Box). 4. Histologic tissue section with intravascular schizonts showing prominent zoites (arrows). Muscle fibers (M).



Figures 5-9. *Sarcocystis capracanis*. 5. Cyst wall with palisade-like villar protrusions and compartmentalized arrangement of zoites (Z) and metrocytes (Me). 6. Portion of the cyst wall showing spacing of villar protrusions (VP) and serrated VP wall. Note marked damage to surrounding host tissues (HT). Sections of zoites (Z) and metrocyte (Me). 8. Cyst wall with VP and numerous lightly-stained amylopectin granules in zoites (Box). 9. Cyst wall showing VP and primary cyst wall with undulations/tubular extensions (arrows) and granular layer (GL).

sarcocysts about 15-30 μ m across exhibited no apparent zoite compartments (Fig. 2). In both histologic and semithin tissue sections intravascular schizonts and parasites enroute to parasitization of muscle fibers were evident (Figs. 3 & 4).

The sarcocysts possess distinct striated cyst wall (Fig. 5), 2.2-3.17 μ m thick with tightly packed palisade-like villar protrusions (VP) (Figs. 6 & 8). Inside the

sarcocysts are groups of densely-stained zoites and lightly-stained metrocytes, showing distinct septal partitions (Figs. 5 & 7). Most VP are spaced 1.1-1.4 μ m apart and possess microfilaments and electron-dense wavy wall (Figs. 6 & 8). The basal and distal segments of the VP measured 0.41-0.85 μ m and 0.15-0.29 μ m, respectively. The 0.15-0.18 μ m thick primary cyst wall (PCW) bears prominent and evenly distributed undulations or tubular extensions interspersed between

the VP (Fig. 9). The granular layer (=ground substance) 0.66-0.77 μ m thick is confluent with the villar core and septae enclosing the zoites (Figs. 8 & 9). The sarcocyst of *S. capracanis* typifies the Type 14 cyst wall (Dubey et al. 1989).

The presence of sarcocysts in esophageal and diaphragm muscle corroborates earlier reports in goats (Singh et al. 1990; Woldenmeskel & Gebreab 1996). Immature and fully developed *S. capracanis* has been demonstrated in the spinal cord and liver of goats (Collins et al. 1980; Dubey et al. 1984). Considering the limitation in the tissue samples examined, we do not preclude the possibility of infection of other internal organs as earlier reported. The fusiform sarcocysts isolated in the present study were smaller (100-200 μ m by 7-13 μ m) compared to those sarcocysts (35-1000 μ m by 20-100 μ m) reported by Dubey et al. (1984). Moreover, the rounded sarcocysts we noted bearing unclear septal partitions may represent another etiologic species of goat sarcocystosis or possibly a developmental form of *S. capracanis*.

The striated palisade shape cyst wall of *S. capracanis* we observed bears similarities with earlier studies (Fischer, 1979; Aryeetey et al. 1980; Dubey et al. 1984; Saito et al. 1996). The VP length and width (1.1-3 μ m by 0.15-0.85 μ m) approximate those of the sarcocysts (1.8-2.8 μ m by 0.41-0.61 μ m) isolated at 64 days post-inoculation (DPI) by Dubey et al. (1984). Thickness of the granular layer of sarcocysts isolated approximates that of the sarcocysts obtained at 64 DPI (Dubey et al. 1984), though thicker compared to the sarcocysts isolated from goats at 56, 92 and 118 DPI (Aryeetey et al. 1980). The variations may have been influenced by differences in the source of sarcocysts, i.e from naturally-infected goats in the present study as against experimentally-exposed goats in earlier reports. In the presence of morphological variations in the wall of *Sarcocystis* belonging to the same species or different strains, Dubey et al. (1989) attribute this to possible influence of age and developmental stage of the parasite, host cell parasitized and difference in muscle tissue processing employed.

Ultrastructurally, *S. capracanis* exhibits resemblance with other species identified as having Types 14, 15, 16 or 17 sarcocyst wall, such as: *Sarcocystis gracilis* Ratz, 1908 of the roe deer (*Capreolus capreolus*); *Sarcocystis odoi* Dubey and Lozier, 1983, and *Sarcocystis odoicoileocanis* Crum, Fayer and Prestwood, 1981 of the white-tailed deer (*Odoicoileus virginianus*); *Sarcocystis tarandivulpes* Gjerde, 1984, *Sarcocystis rangiferi* Gjerde, 1984, and *Sarcocystis tarandi* Gjerde, 1984 of the reindeer (*Rangifer tarandus tarandus*) (Dubey et al. 1989). While our study represents the first documented case

of sarcocystosis capracanis in the country, it would be valuable to continue to identify other probable etiologic species infecting goats, and in the near future to carry out experimental exposure studies to establish the parasite's definitive host(s).

Acknowledgments

We acknowledge the National Research Council of the Philippines, Department of Science and Technology, Philippines, the International Foundation for Science (IFS), Stockholm, Sweden (Research Grant Number B/2652-2), and the College of Science Research Council, De La Salle University-Manila for the encouragement and the financial support.

References

- Aryeetey M., Mehlhorn H & Heydorn AO. 1980. Electron microscopic studies on the development of *Sarcocystis capracanis* in experimentally infected goats. *Zentralblatt für Bacteriologie. Orig. A* 247:543-556.
- Claveria FG & Cruz MJ. 1999. Light microscopic and ultrastructural studies on *Sarcocystis* spp. infection in Philippine water buffaloes (*Bubalus bubalis*). *Journal of Protozoology Research* 9:17-25.
- Claveria FG & Cruz. MJ. 2000. *Sarcocystis levinei* infection in Philippine water buffaloes (*Bubalus bubalis*). *Parasitology International* 48: 243-247.
- Claveria FG, San Pedro-Lim R, Cruz MJ, Nagasawa H, Suzuki N & De La Peña C. 2001a. Ultrastructural studies of *Sarcocystis cruzi* (Hasselmann, 1926) Wenyon, 1926 infection in cattle (*Bos taurus*): Philippine cases. *Parasite* 8:251-254.
- Claveria FG, Cruz-Flores MJ & De La Peña C. 2001b. *Sarcocystis miescheriana* infection in domestic pigs (*Sus scrofa*) in the Philippines. *Journal of Parasitology* 87:918-919.
- Collins GH, Sutton RH & Charleston WAG. 1980. Studies on *Sarcocystis* species V: A species infecting dogs and goats: Observations on the pathogenicity and serology of experimental sarcocystosis in goats. *New Zealand Veterinary Journal* 28:156-158.
- Dubey JP. 1980. Coyote as a final host for *Sarcocystis* species in goats, sheep, cattle, elk, bison and moose in Montana. *American Journal of Veterinary Research* 41:1227-1229.
- Dubey JP, Speer CA, Epling GP & Blixt JA. 1984. *Sarcocystis capracanis*: Development in goats,

- dogs and coyotes. International Goat and Sheep Research 2:252-265.
- Dubey JP, Speer CA & Fayer R. 1989. Sarcocystosis of Animal and Man. pp. 1-125. CRC Press Inc., Boca Raton, Florida.
- Fischer G. 1979. Die entwicklung von *Sarcocystis capracanis* n. spec. in der ziege. Inaugural-Dissertation zur Erlangung der Würde eines Doctor Medicinae Veterinariae an der Freien Universitat Berlin. Journal No. 973. 45 pp.
- Foreyt WJ. 1989. *Sarcocystis* sp. In mountain goats (*Oreamnos americanus*) in Washington: prevalence and search for the definitive host. Journal of Wildlife Diseases 25:619-622.
- Huong LTT, Dubey JP & Ugglä A. 1997. Redescription of *Sarcocystis levinei* Dissanaiké and Kan 1978 (Protozoa: Sarcocystidae) of the water buffalo (*Bubalus bubalis*). Journal of Parasitology 83:1148-1152.
- Parairo J, Manuel M & Icaldo F. 1988. Ultrastructural studies of the cyst wall of *Sarcocystis* spp. in Philippine carabaos. Philippine Journal of Veterinary and Animal Sciences 14:40-54.
- Saito M, Shibata Y, Kobayashi T, Kobayashi M, Kubo M & Itagaki H. 1996. Ultrastructure of the cyst wall of *Sarcocystis* species with canine host in Japan. Journal of Veterinary Medical Science 58:861-867.
- Singh KP, Agrawal MC & Shah HL. 1990. Prevalence of sarcocysts of *Sarcocystis capracanis* in oesophagus and tail muscles of naturally infected goats. Veterinary Parasitology 36:153-155.
- Tongson M. & Molina, R. 1979. Light and electron microscope studies on *Sarcocystis* sp. of the Philippine buffaloes (*Bubalus bubalis*). Philippine Journal of Veterinary Medicine 18:16-31.
- Woldemedkel M & Gebreab F. 1996. Prevalence of sarcocysts in livestock in northwest Ethiopia. Zentralblatt Veterinärmedizin Reihe B 43:55-58.